

Royal Free Hospital

Pond Street
London NW3 2QG

Name: [REDACTED]
Patient ID: 0000
DOB: 30 June 1949

Sex: Female
Ethnicity: White

Height: 160.0 cm
Weight: 59.0 kg
Age: 52

Referring Physician: DR CHRISTIAN

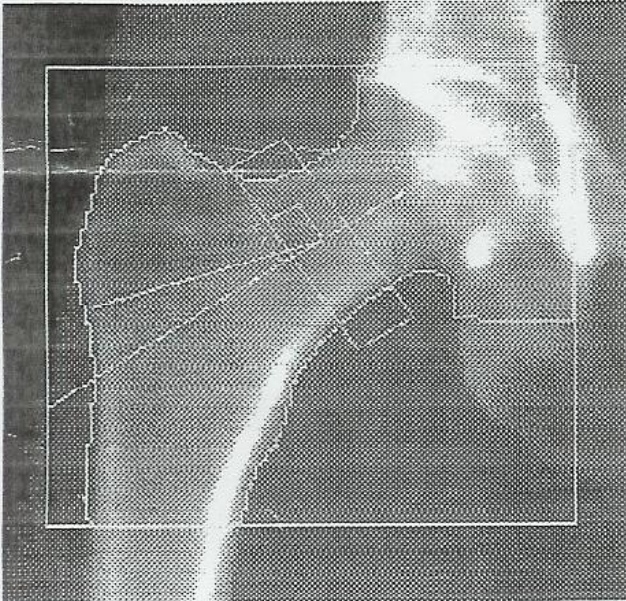


Image not for diagnostic use
107 x 102

Scan Information:

Scan Date: 26 September 2001 ID: A0926010M
Scan Type: f Right Hip
Analysis: 26 September 2001 12:18 Version 11.1
Right Hip
Operator: DW
Model: QDR 4500W (S/N 47096)
Comment:

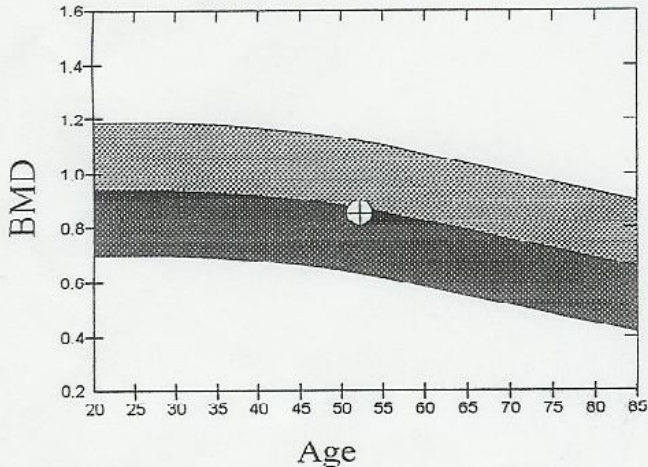
DXA Results Summary:

| Region | Area (cm ²) | BMC (g) | BMD (g/cm ²) | T-Score | Z-Score |
|--------------|-------------------------|--------------|--------------------------|-------------|-------------|
| Neck | 4.53 | 3.11 | 0.688 | -1.5 | -0.6 |
| Troch | 11.71 | 7.74 | 0.661 | -0.4 | 0.1 |
| Inter | 20.34 | 20.43 | 1.004 | -0.6 | -0.3 |
| Total | 36.58 | 31.28 | 0.855 | -0.7 | -0.2 |
| Ward's | 1.08 | 0.56 | 0.517 | -1.9 | -0.4 |

Total BMD CV 1.0%

WHO Classification: Normal
Fracture Risk: Not Increased

Total



Reference curve and scores matched to White Female

Physician's Comment: