

# Royal Free Hospital

Pond Street  
London NW3 2QG

Name: [REDACTED]  
Patient ID: 0000  
DOB: 30 June 1949

Sex: Female  
Ethnicity: White

Height: 166.0 cm  
Weight: 61.0 kg  
Age: 53

Referring Physician: DR CHRISTIAN

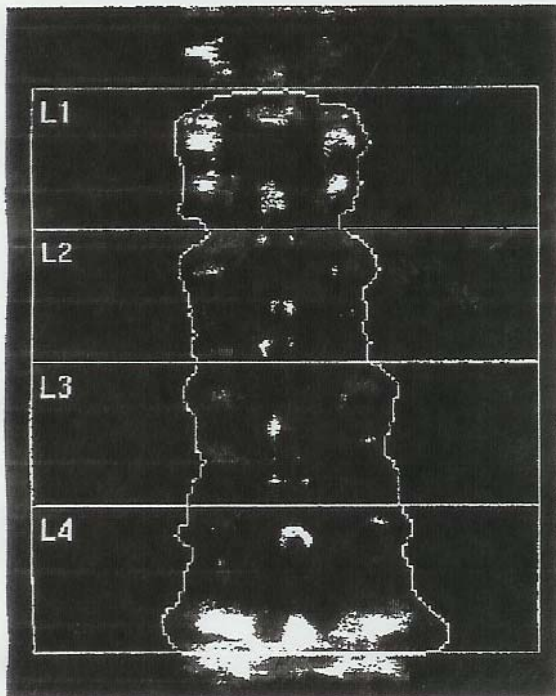


Image not for diagnostic use  
116 x 139

### Scan Information:

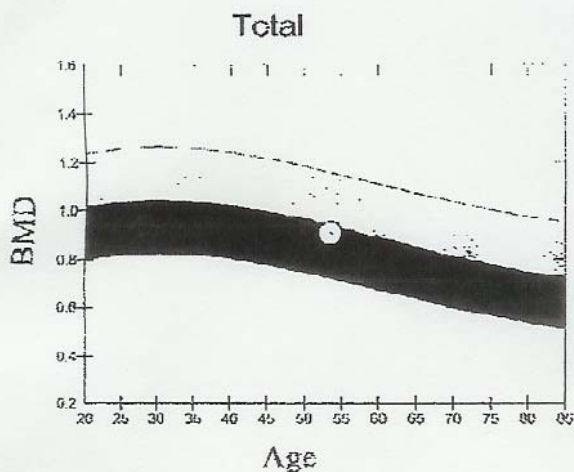
Scan Date: 06 December 2002 (ID: A1206020Q)  
Scan Type: a Lumbar Spine  
Analysis: 06 December 2002 12:43 Version 11.2  
Lumbar Spine  
Operator:  
Model: QDR 4500W (S/N 47096)  
Comment:

### DXA Results Summary:

Region	Area (cm <sup>2</sup> )	BMC (g)	BMD (g/cm <sup>3</sup> )	T-Score	Z-Score
L1	12.79	9.66	0.755	-1.5	-0.7
L2	13.46	11.10	0.825	-1.8	-0.9
L3	15.98	13.48	0.844	-2.2	-1.2
L4	20.49	22.63	1.105	-0.1	0.9
<b>Total</b>	<b>62.72</b>	<b>56.87</b>	<b>0.907</b>	<b>-1.3</b>	<b>-0.3</b>

Total BMD CV 1.0%

WHO Classification: Osteopenia  
Fracture Risk: Increased



### Physician's Comment:

Improvement in spine but deterioration in hip. Dr AJW Hilson.

Reference curve and scores matched to White Female

Source: Hologic