

Royal Free Hospital

Pond Street
London NW3 2QG

Name: [REDACTED]
Patient ID: 0000
DOB: 30 June 1949

Sex: Female
Ethnicity: White

Height: 166.0 cm
Weight: 61.0 kg
Age: 53

Referring Physician: DR CHRISTIAN

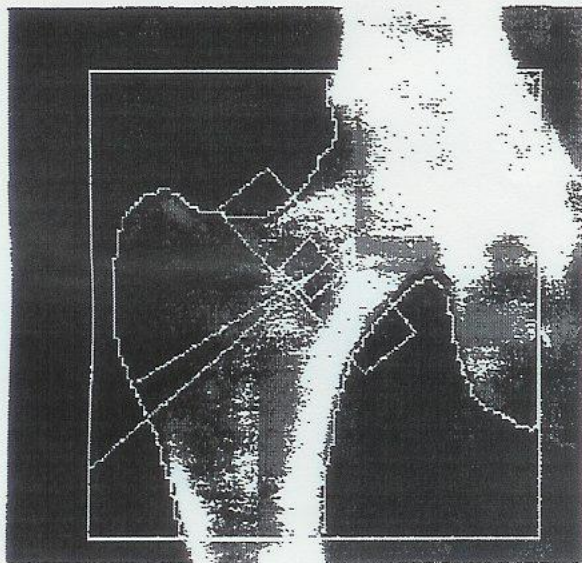


Image not for diagnostic use
99 x 104

Scan Information:

Scan Date: 06 December 2002 ID: A12060208
Scan Type: a Right Hip
Analysis: 06 December 2002 12:46 Version 11.2
Right Hip
Operator:
Model: QDR 4500W (S/N 47096)
Comment:

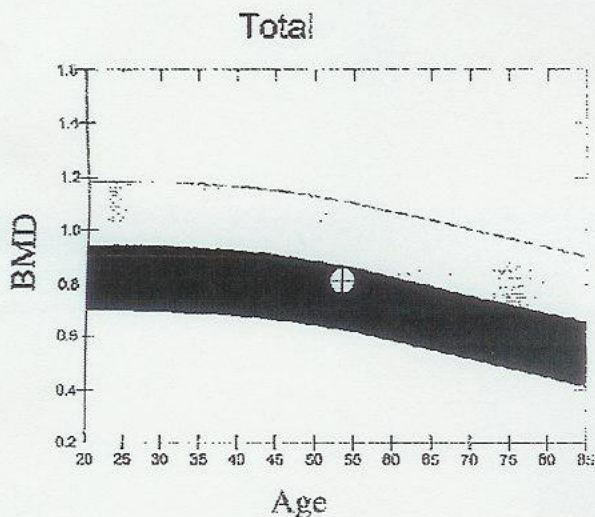
DXA Results Summary:

| Region | Area (cm ²) | BMC (g) | BMD (g/cm ²) | T-Score | Z-Score |
|--------------|-------------------------|--------------|--------------------------|-------------|-------------|
| Neck | 5.10 | 3.49 | 0.684 | -1.5 | -0.5 |
| Troch | 11.14 | 7.09 | 0.636 | -0.7 | -0.1 |
| Inter | 16.41 | 15.99 | 0.975 | 0.8 | 0.4 |
| Total | 32.65 | 26.57 | 0.814 | -1.1 | -0.4 |
| Ward's | 1.09 | 0.59 | 0.540 | -1.7 | -0.1 |

Total BMD CV 1.0%

WHO Classification: Osteopenia

Fracture Risk: Increased



Reference curve and scores matched to White Female

Source: NHANES

Physician's Comment: